

Integration of Amniotic Membrane - Clinical Case

Manolova Y., Stoycheva Z.

Department of Ophthalmology and Visual Science, Medical University of Varna

Specialised Eye Hospital – Varna, Bulgaria

Abstract - In recent years amniotic membrane (AM) established itself in reconstructive surgery of the anterior ocular segment as a tool of choice with pathologies that are difficult to treat. With extensive corneal ulcers that yield to conventional medical treatment, the transplantation of AM is a necessity and currently the only solution. In order to obtain optimal best result it is important to be familiar in details with the properties of AM and the types of surgical techniques for its transplantation on the anterior ocular surface. Our aim is to present a patient with an extensive and deep corneal ulcer treated with amniotic membrane transplantation (AMT). After AMT a stabilization of the corneal thickness was achieved by integration of amniotic tissue into the host tissue.

Keywords - Amniotic membrane, integration, toxic keratitis.

1. INTRODUCTION

In recent years amniotic membrane established itself in reconstructive surgery of the anterior ocular segment as a tool of choice with pathologies that are difficult to treat. This translucent three-layer membrane is the inner layer of the placenta and is 0,02-0,05mm thick (1). Its transparency is determined by the fact that it contains no nerve fibers, smooth muscle cells, lymph and blood vessels (2). AM is not just avascular tissue. It has multiple metabolic functions such as transport of water and soluble substances and producing bioactive factors, including vasoactive peptides, growth factors and cytokines. The advantage of AM is that it resembles corneal and conjunctival tissue. The basal membrane of the amnion is one of the thickest membranes in the human body that can withstand the current storage techniques. It contains mainly collagen type I, III, IV, V and VII found in the conjunctival and corneal basal membranes in addition to fibronectin and laminin, large amounts of proteoglycans and heparin sulfate. These components are available in the stromal matrix of AM. The most important tensile strength of AM is performed by collagen in the compact layer. The arrangement of the interstitial collagen gives additional strength to the tissue regarding the mechanical influences. The presence of integrin alpha 6/beta 4 as main ligands in the basal membrane involved in the construction of hemidesmosomes-like structures favors the adhesion and stabilization of epithelial stem cells for the wound healing. This facilitates the migration of the epithelial cells, enhances the adhesion of basal epithelial cells, stimulates epithelial differentiation and prevents apoptosis (3), (4). AM possesses anti-inflammatory, anti-cicatricial and anti-

angiogenic properties (5). The ability to recover the defects can be explained with its regeneration function that is due on one hand to the stimulation of the epithelialization, life extension, life cycle and clonogenicity of the epithelial cells. On the other hand when used as a filler for the inlay of deep defects AM shows signs of integration into the target tissue, resulting in a stabilization of the anterior surface. The integration can be observed by biomicroscopy, in vivo confocal microscopy (IVCM) and anterior segment optical coherent tomography (AS-OCT). Manolova et al. have described cases of biomicroscopic and IVCM data for integration into the host tissue (6). Resch et al. have described a light microscopic evidence for integration of amnion at different levels in the corneal tissue (7).

2. CASE REPORT

A 39-year-old patient who came to the hospital complaining of decreased vision, irritation, redness, pain, photophobia and watery right eye. About 20 days before being directed to the hospital he reported that at work he flash burnt his eye and consultative examination found out a corneal defect. According to data from the medical records, the right eye had BCVA of 20/30. The patient was treated with antibiotic drops and an epithelotonic gel without any success. Without a doctor's prescription but because of the pain, the patient applied Alkain several times a day. Upon entering the clinic, BCVA of the right eye was a movement of a hand and of the left eye – 20/20. TOD = N (palpable), TOS = 17.5 mmHg. Objective finding during the study showed moderate swelling of the eyelids, severe mixed hyperemia, cornea with greatly reduced transparency and deep broad corneal defect. The pupil was irregular in shape, with posterior synechiae and reacted slowly to light, further details posteriorly could not be seen. The patient was explained the toxic effects of Alkain. Treatment with midriatik was prescribed in order to rupture the synechiae and antibiotic drops - a combination of an aminoglycoside and quinolone, nonsteroidal anti-inflammatory drugs and repeated instillation of epitelotonichni gels. A transplantation of AM onlay was performed. Due to the lack of significant improvement after a period of 10 days a second surgery followed – a transplantation of AM multilayer technique to fill the corneal defect. The filler was sutured to the cornea with interrupted 10-0 suture Nylon. A monolayer AM

onlay is put on the top and sutured with 8-0 vicryl interrupted suture to the conjunctiva and episclera (Fig 1).

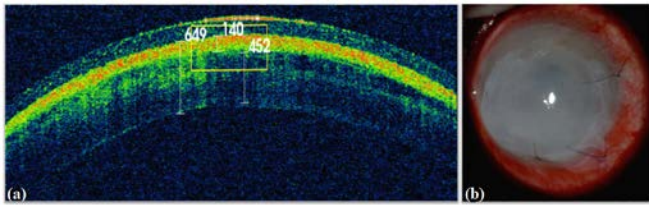


Fig. 1. (a) AS-OCT images. Measurement of corneal and amniotic membrane thickness 2ND day after the surgery. The dividing line, which distinguishes the amnion from the underlying tissue is clearly seen. (b) One week after AMT – the first biomicroscopic signs of integration of amnion are visible.

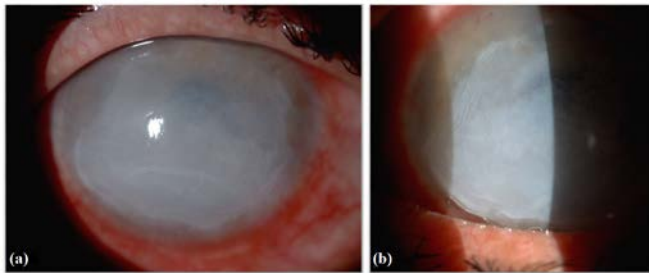


Fig. 2. a) and b) 20 days after AMT – integration of the filler into the corneal tissue; Stabilization of the cornea; Lack of subjective complaints.

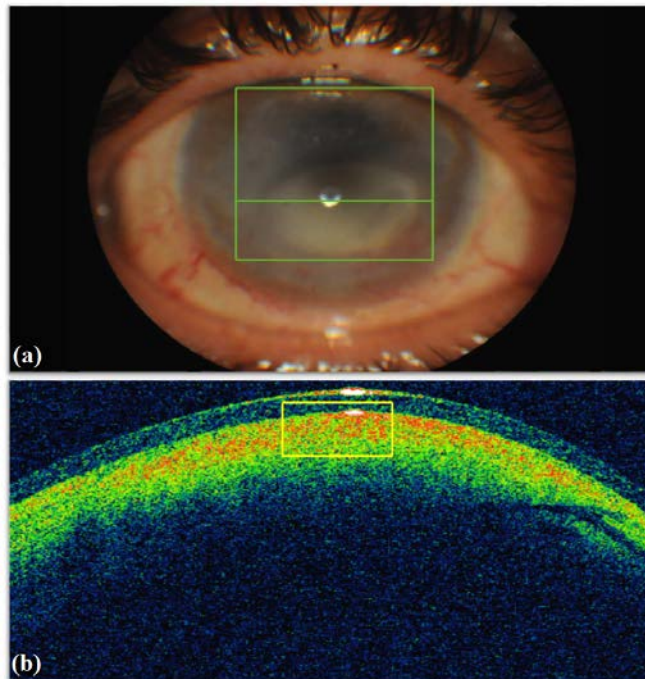


Fig. 3 AS-OCT images – 1 month after the multilayer transplantation of AM. Integration of AM in the stroma. The thickening of the anterior corneal layers can be seen (their substitution with amniotic tissue) and the fusion of amnion with the stroma of the corneal (a clearly distinguishing demarcation line is missing).

The patient was prescribed antibiotic drops, NSAIDs and epithelotonic gels. One week later corneal thickness was stabilized and the subjective complaints - photophobia,

secretion, hyperemia were improved and there was also a significant reduction of pain (Fig 2). Through biomicroscopy and by using AS-OCT it was found an integration of AM in the cornea. One month later the cornea had a substantially stabilized thickness, there was no pain, tearing, photophobia and hyperemia. BCVA of the right eye was 20/400 (Fig 3).

3. DISCUSSION

The qualities of the amniotic membrane as a scaffold for regeneration and stabilization filler for deep ulcerative defects make it attractive in transplant surgery on the anterior surface.

Four main effects for regeneration of the corneal epithelium are described:

- (1) facilitating the epithelial cell migration;
- (2) enhancement of cell adhesion of the basal epithelium (8), (9), (10)
- (3) facilitating epithelial cell differentiation (11), (12), (13)
- (4) prevention of epithelial apoptosis (14), (15)

AM also improves the sensitivity of the cornea and the stability of the tear film by an unknown mechanism. The ability of the basal membrane of the amnion to facilitate the expansion of progenitor cells can explain the application of AM in the treatment of partial deficiency of limbal stem cells. AM allows the retention of the tear film, thereby provides a moist environment for the re-epithelialization of the ocular surface. It has good oxygen permeability and conductivity which provides sufficient oxygenation for the epithelial cells, which is in contrast to many synthetic materials and it was demonstrated in the publication of Tsuyoshi Yoshita et al. the oxygen permeability was examined (Dk), the oxygen portability (Dk/t) through AM, as well as tear oxygen tension under AM in rabbits. The water content of AM was measured and compared with that of the soft contact lens (SCL). The results showed significantly higher values in the water content (96.8 +/- 0.8% against 78%) which provides higher Dk and Dk/t in the AM in comparison with SCL. The average concentration of oxygen under AM was also higher in comparison with that of the SCL (94.9 +/- 2.9 versus 59.1 +/- 4.9 mm Hg). Such evidence supports the statement that AM can serve as a dressing in the treatment of persistent corneal epithelial defects (16). In these cases, it is more correct to use a technique called "onlay" (epithelial side of the AM is in contact with the corneal surface), thus facilitating healing, influences the inflammation and decreases the pain syndrome (17).

It is necessary to use multilayer technique – inlay and onlay in cases of deep stromal corneal defects. One or more layers of AM may be used for filling the corneal

ulcer, the arrangement of the layers is not important, with the exception of the uppermost layer, which must be placed with the epithelium upward to allow coverage of corneal epithelial cells. When the re-epithelialization of the top layer of the AM occurs, the remaining parts of pieces of AM, which were placed to fill the defect may be incorporated into the cornea. It results in thickening and stabilization of the corneal defect (18). First Seitz et al. histologically demonstrated that AM was integrate into the tissue of the recipient (7). Nubile et al. first made in vivo analysis of stromal integration of AM after multilayer tranplantsation of AM, then other authors found consistency of data among themselves that match our research (19). IVCN is a laborious study which monitors the microstructural changes that occur in both the AM and the tissue of the host after transplantation. It is a valuable research method. In clinical practice besides the bioscopic study, AS-OCT is a valuable and considerably more easy and non-invasive method, which gives a good, reliable information about the status of the corneal thickness and the changes that occur after the transplantation of AM. In this paper, our goal was to demonstrate the importance of making the correct decision on the type of surgical technique for the transplantation of AM and besides the biomicroscopic data for the presence of integration and stability of the cornea with corneal defects, it is important to monitor the condition of the anterior surface through AS-OCT. When the inflammation subsides AM inlay type can be put. Using this technique when the inflammation is active faces the risk of increasing the infection and its in depth penetration. Thus, when there is an active inflammation which cannot be controled with drug therapy we recommend as a first stage an AMT onlay type and as a second step inlay and onlay type.

4. CONCLUSION

The amniotic membrane is immune privilege tissue, which is an excellent matrix for the recovery of deep defects of the cornea aiming at stabilizing its surface and as a probable second step of performing corneal transplantation in order to improve the visual function and long-acting effect of the performed procedure, as well as reducing the risk of transplant rejection. Selecting the right surgical technique and the time to perform it is crucial for the final result.

REFERENCES

- [1] Dua HS, Gomes JAP, King AJ, Maharajan VS. The amniotic membrane in ophthalmology. *Surv Ophthalmol.* 2004 Feb;49(1):51–77.
- [2] Niknejad H, Peirovi H, Jorjani M, Ahmadiani A, Ghanavi J, Seifalian AM. Properties of the amniotic membrane for potential use in tissue engineering. *Eur Cell Mater.* 2008;15:88–99.
- [3] Diwan SB, Stevens LC. Development of teratomas from the ectoderm of mouse egg cylinders. *J Natl Cancer Inst.* 1976 Oct;57(4):937–42.
- [4] Enders AC, King BF. Formation and differentiation of extraembryonic mesoderm in the rhesus monkey. *Am J Anat.* 1988 Apr;181(4):327–40.
- [5] Silini AR, Cargnoni A, Magatti M, Pianta S, Parolini O. The Long Path of Human Placenta, and Its Derivatives, in Regenerative Medicine. *Front Bioeng Biotechnol.* 2015;3:162.
- [6] Manolova Y, Stoycheva Z, Yordanov Y, Grupcheva C. Amniotic membrane transplantation - analysis of structural characteristics in amniotic membrane transplant and corneal ulcers. *A Scr Sci Medica [Internet].* 2017 Apr 3 [cited 2017 Apr 9];49(1).
- [7] Resch MD, Schlötzer-Schrehardt U, Hofmann-Rummelt C, Sauer R, Kruse FE, Beckmann MW, et al. Integration patterns of cryopreserved amniotic membranes into the human cornea. *Ophthalmology.* 2006 Nov;113(11):1927–35.
- [8] Keene DR, Sakai LY, Lunstrum GP, Morris NP, Burgeson RE. Type VII collagen forms an extended network of anchoring fibrils. *J Cell Biol.* 1987 Mar;104(3):611–21.
- [9] Sonnenberg A, Calafat J, Janssen H, Daams H, van der Raaij-Helmer LM, Falcioni R, et al. Integrin alpha 6/beta 4 complex is located in hemidesmosomes, suggesting a major role in epidermal cell-basement membrane adhesion. *J Cell Biol.* 1991 May;113(4):907–17.
- [10] Terranova VP, Lyall RM. Chemotaxis of human gingival epithelial cells to laminin. A mechanism for epithelial cell apical migration. *J Periodontol.* 1986 May;57(5):311–7.
- [11] Guo M, Grinnell F. Basement membrane and human epidermal differentiation in vitro. *J Invest Dermatol.* 1989 Sep;93(3):372–8.
- [12] Kurpakus MA, Stock EL, Jones JC. The role of the basement membrane in differential expression of keratin proteins in epithelial cells. *Dev Biol.* 1992 Apr;150(2):243–55.
- [13] Streuli CH, Bailey N, Bissell MJ. Control of mammary epithelial differentiation: basement membrane induces tissue-specific gene expression in the absence of cell-cell interaction and morphological polarity. *J Cell Biol.* 1991 Dec;115(5):1383–95.
- [14] Boudreau N, Sympon CJ, Werb Z, Bissell MJ. Suppression of ICE and apoptosis in mammary epithelial cells by extracellular matrix. *Science.* 1995 Feb 10;267(5199):891–3.
- [15] Boudreau N, Werb Z, Bissell MJ. Suppression of apoptosis by basement membrane requires three-dimensional organization and withdrawal from the cell cycle. *Proc Natl Acad Sci U S A.* 1996 Apr 16;93(8):3509–13.
- [16] Yoshita T, Kobayashi A, Sugiyama K, Tseng SCG. Oxygen permeability of amniotic membrane and actual tear oxygen

tension beneath amniotic membrane patch. *Am J Ophthalmol.* 2004 Sep;138(3):486–7.

- [17] Burman S, Tejwani S, Vemuganti GK, Gopinathan U, Sangwan VS. Ophthalmic applications of preserved human amniotic membrane: a review of current indications. *Cell Tissue Bank.* 2004;5(3):161–75.
- [18] Prabhasawat P, Tesavibul N, Komolsuradej W. Single and multilayer amniotic membrane transplantation for persistent corneal epithelial defect with and without stromal thinning and perforation. *Br J Ophthalmol.* 2001 Dec;85(12):1455–63.

Nubile M, Dua HS, Lanzini M,

AUTHOR'S PROFILE

Manolova Y, MD, PhD is an Assistant Professor in the department of Ophthalmology and Visual Science at the Medical University of Varna, Bulgaria. Her clinical interests include medical and surgical management of anterior segment diseases, glaucoma and cataract surgery. Dr. Manolova graduated cum laude at the Medical University of Varna, Bulgaria in 1997 and completed her ophthalmology residency in 2004. In addition to her clinical practice, Dr. Manolova is actively involved in clinical and translational ophthalmic research. She published many research articles and presents frequently in the national and international conferences. She is a member of a number of Bulgarian, European and International learned societies.

Stoycheva Z. is a PhD student and a resident in Ophthalmology at the Medical University of Varna, Bulgaria. Her areas of interests are anterior segment diseases and glaucoma.